

Effect of Administration Ethanol Leaf Extract of *Terminalia Chebula* on Liver of Wister Rat

Joseph Oyepata Simeon^{1*}, Modupe Builders², Wazis Chama Haruna³, Joseph Opeyemi Tosin⁴, Sabastine Aliyu Zubairu⁵, Musa Tabitha Lubo⁶, Moh'd A. Sadiq⁷

^{1,2}Department of Pharmacology, Faculty of Pharmacy, Bingham University, Nasarawa, Nigeria

³Department of Pharmacology and Toxicology, Faculty of Pharmacy, University of Maiduguri, Bornu State, Nigeria.

⁴Department of Pharmacology, Faculty of Basic Medical Sciences, University of Port Harcourt, Rivers State, Nigeria

^{5,6,7}Department of Pharmacognosy, Faculty of Pharmacy, Gombe State University, Gombe State, Nigeria.

*Corresponding Author

Abstract:-

Introduction/Aim: Subacute toxicity tests are intended to evaluate the toxicity of the chemical after repeated administration and also to help in establishing doses for the longer-term subchronic studies. Plant has been one of the original and earliest source for correcting physiological changes in the humans body. *Terminalia chebula*, commonly known as black- or chebulic myrobalan, is a species of *Terminalia*, widely used in South Asia from India and Nepal east to southwest China (Yunnan), and south to Sri Lanka, Malaysia, and across Africa. It is widely used in management of various illness. This work is aimed at evaluating the toxic effect of *Terminalia chebula* on liver of wister rats.

Method: rats of either sex were selected. Group 1 received distilled water (10 ml/kg), while group 2, 3 and 4 received *Terminalia Chebula* 200, 400 and 800 mg/kg respectively. Animals were kept in standard cages and given access to the extract, water and food orally for 28 days, after which they were weighed and sacrificed. Blood was collected by cardiac puncture and taken immediately for hematological and chemo pathological analysis. The liver and heart were also harvested for histological study of the effect of the plant using haematotoxilin and eosin (H&E) staining technique.

Result: There was Significant (P<0.05) decrease in RBC, HGB, MCV, while there was no significant change in the level of neutrophils, basophiles, eosinophiles and platelets. There were also significant (P<0.05) increase in ALP, BILT and BILD. The liver showed slight vascular congestion and lymphocyte hyperplasia at 200 and 800 mg/kg dose while there was normal features for both 400 mg/kg and control.

Conclusion: *Terminalia Chebula* should be used with caution because it may have slight effect on the liver when taken for a prolonged period of time.

Keywords: *Terminalia Chebula*, rats, liver, heart

I. INTRODUCTION

The body offers various reactions to foreign substances that infiltrate it¹. For the purpose of comprehensively determining what kind of effect a chemical substance has, or may have, on the body at that time, a systemic toxicity test observes and evaluates the systemic changes on an animal administered with the substance in question². Plant-derived

medicines are used in all civilizations and cultures and, hence, plants have always played a key role in health care systems worldwide. In most developing countries, the indigenous modes of herbal treatment are a part of the culture and the dominant method of healing therapy. These remedies, with a considerable extent of effectiveness, are socially accepted, economically viable and, mostly, are the only available source³. Plants used in traditional medicine, therefore, have a critical role in the maintenance of health all over the world. The drugs of herbal, herbo-mineral, and animal origin have been used by the traditional healers to maintain health and treat diseases since antiquity. Such medicines are widely used in Africa and Asia, including India and China^{3,4}. Due to the adverse side-effects, and also the development of resistance against synthetic drugs, the uses of plant-derived drugs are becoming popular in developed countries also⁴.

The liver performs the normal metabolic homeostasis of the body as well as biotransformation, detoxification and excretion of many endogenous and exogenous compounds, including pharmaceutical and environmental chemicals. Drug-induced hepatotoxicity is a major cause of iatrogenic diseases, accounting for one in 600 to one in 3500 of all hospital admissions⁵.

Terminalia chebula tree is about 50-80 feet tall in height⁶. It has round crown and spreading branches. The bark is dark brown with some longitudinal cracks. Leaves are ovate and elliptical, with two large glands at the top of the petiole. The flowers are monoecious, dull white to yellow, with a strong unpleasant odour, borne in terminal spikes or short panicles. *T. chebula* is found in the Sub Himalayan tracks from Ravi eastwards to West Bengal and Assam, ascending up to the altitude of 1500 m in the Himalayas. This tree is wild in forests of Northern India, central provinces and Bengal⁷. The tree is also spread across Africa. The fruit is mild laxative, stomachic, tonic, alterative, antispasmodic^{7,8}. It is useful in ophthalmic, hemorrhoids, dental caries, bleeding gums, ulcerated oral cavity. Its paste with water is found to be anti-inflammatory, analgesic and having purifying and healing capacity for wounds. Its decoction is used as gargle in oral ulcers, sore throat. Its powder is a good astringent dentifrice in

loose gums, bleeding and ulceration in gums⁹. It is good to increase appetite, digestive aid, liver stimulant, stomachic, gastrointestinal prokinetic agent, and mild laxative. The powder of *T. chebula* fruits has been used in chronic diarrhea. It is used in nervous weakness, nervous irritability. It promotes the receiving power of five senses. It is adjuvant in hemorrhages due to its astringent nature and good for chronic cough, chorizo, sore throat as well as asthma. *Terminalia chebula* is the main ingredient in the Ayurvedic formulation *Triphala* which is used for kidney and liver dysfunctions. The dried fruit is also used in Ayurveda as a purported antitussive, cardiogenic, homeostatic, diuretic, and laxative. The aim of this experiment is to evaluate the effect of ethanol extract of *Terminalia chebula* on the liver of wister rat.

II. MATERIALS AND METHOD

Animals

Male and female Wister rats were obtained from Bingham University, Animal House. They were maintained on standard animal pellets and given water *ad libitum*. Permission and approval for animal studies were obtained from the College of Health Sciences Animal Ethics Committee of Bingham University.

Plant collection

Fresh leaves of *Terminalia chebula* were collected from its natural habitat from nearby Karu village, Nasarawa State, Nigeria. The plant was authenticated from Department of Botany, Bingham University, Nasarawa State, Nigeria.

Plant extraction

The leaves were shadow dried for two weeks. The dried plant material was further reduced into small pieces and pulverized. The powdered material was macerated in 70% ethanol. The liquid filtrates were concentrated and evaporated to dryness at 40°C *in vacuum* using rotary evaporator. The ethanol extract was stored at -4°C until used.

Animal study

Twenty four (24) rats of either sex (125-300g) were selected and randomized into four groups of six rats per group. Group 1 served as the control and received normal saline (10ml/kg) while the rats in groups 2, 3 and 4 were giving 200, 400, and 800 mg/kg of extract respectively. The weights of the rats were recorded at the beginning of the experiment and at weekly intervals. The first day of dosing was taken as D₀ while the day of sacrifice was designated as D₂₉.

Haematological analysis

The rats were sacrificed on the 29th day of experiment. Blood samples were collected via cardiac puncture. The blood was collected into sample bottles containing EDTA for hematological analysis such as Hemoglobin concentration, white blood cell counts (WBC), differentials (neutrophils, eosinophils, basophils, lymphocyte and monocyte), red blood

cell count (RBC), platelets and hemoglobin (Hb) concentration using automated Haematology machine (Cell-Dyn, Abbott, USA).

Biochemical analysis

A Portion of the blood was collected used to estimate biochemical parameters including liver enzymes: alanine amino transaminase (ALT), aspartate amino transaminase (AST), alkaline phosphatase (ALP), albumin (ALB), total protein (TP), conjugated bilirubin (BILD), unconjugated bilirubin (BILT) using a photoelectric colorimeter.

Histopathology:

Tissues collected were preserved in 10% formal saline solution. Small block of the tissues were taken from liver and fixed in Bouin's fluid for 16 to 24 hours. Tissue were slices and processed according to the method described by (Lison, 1960) and stained with haematoxylin and eosin.

III. RESULTS

Effect of sub-acute oral administration of Terminalia chebula on hematological parameters in rats

Terminalia chebula caused significant ($p < 0.05$) decrease in the level of red blood cell, hemoglobin, platelet etc. and significantly ($p < 0.05$) caused an increase in mean corpuscular hemoglobin concentration in the rats at the dose level of 400 mg/kg compared to the control. The level of basophiles, neutrophils, eosinophils and lymphocytes were however not significantly ($p < 0.05$) affected by mean corpuscular hemoglobin concentration (Table 1).

Statistical analysis

Data were expressed as the Mean \pm Standard Error of the Mean (SEM). Data were analyzed statistically using one-way Analysis of Variance (ANOVA) followed by Dunnett's post hoc test for multiple comparisons between the control and treated groups. Values of $P \leq 0.05$ were considered significant.

Result

Effect of sub-acute oral administration of Terminalia chebula on hematological parameters in rats

Terminalia chebula caused significant ($p < 0.05$) decrease in the level of red blood cell, hemoglobin, platelet etc. and significantly ($p < 0.05$) caused an increase in mean corpuscular hemoglobin concentration in the rats at the dose level of 400 mg/kg compared to the control. The level of basophiles, neutrophils, eosinophils and lymphocytes were however not significantly ($p < 0.05$) affected by mean corpuscular hemoglobin concentration (Table 1).

Effect of sub-acute oral administration of Terminalia chebula on hepatic indices in rats

At 200 mg/kg dose level, *Terminalia chebula* caused significant ($p < 0.05$) decrease in BILD concentration in the treated rats while at 400 mg/kg dose level significant ($p < 0.05$)

increase was obtained in ALP levels, BILD and BILT concentrations when compared to the control. All other parameters studied showed no significant affect (Table 2).

The liver showed vascular congestion, and lymphocyte hyperplasia at 200 mg/kg and 800 mg/kg, while normal features were observed at 400 mg/kg dose and in the control.

Effect of sub-acute oral administration of Terminalia chebula on histology of Liver of rats

Table 1: Effect of sub-acute oral administration of ethanol leaf extract of *Ocimum canum* on hematological parameters in wistar rats

Hematological parameters	Treatment (mg/kg)			
	DW(10ml/kg)	200 mg/kg	400 mg/kg	800 mg/kg
WBC ($\times 10^9/L$)	9.166 \pm 0.772	7.640 \pm 1.429	4.700 \pm 0.556*	8.230 \pm 1.088
RBC ($\times 10^{12}/L$)	9.23 \pm 0.32	9.65 \pm 0.67	7.11 \pm 0.75*	7.81 \pm 0.22
HGB (g/dL)	15.56 \pm 0.56	15.45 \pm 0.88	12.33 \pm 0.76*	15.58 \pm 0.37
HCT (g/dL)	57.18 \pm 2.03	57.60 \pm 3.75	35.67 \pm 3.18*	54.40 \pm 1.82
MCV (fL)	66.45 \pm 0.93	64.40 \pm 1.14	57.77 \pm 0.31*	69.61 \pm 1.73
MCH (pg)	19.17 \pm 0.17	17.80 \pm 1.02	18.83 \pm 0.37	18.80 \pm 0.20
MCHC (g/dL)	29.17 \pm 0.17	27.40 \pm 1.12	32.50 \pm 0.62*	27.60 \pm 0.68
PLT ($\times 10^9/L$)	620.83 \pm 52.81	567.00 \pm 96.41	252.00 \pm 50.38*	670.40 \pm 55.72
LYM (%)	86.83 \pm 4.06	85.00 \pm 4.18	82.83 \pm 5.89	86.40 \pm 3.14
NEUT ($\times 10^9/L$)	11.83 \pm 3.68	11.83 \pm 3.58	14.40 \pm 5.20	13.20 \pm 3.11
EOSI ($\times 10^9/L$)	1.53 \pm 0.34	1.40 \pm 0.76	1.90 \pm 0.22	1.40 \pm 0.43
BASO ($\times 10^9/L$)	1.10 \pm 0.28	2.45 \pm 0.43	2.50 \pm 1.50	3.40 \pm 2.23

Data presented as Mean \pm SEM: n = 6, One way ANOVA, followed by Dunnett's post hoc for multiple comparison *significantly different from the distilled water (DW) control at p<0.05. DW = distilled water.

(WBC = white blood cells, RBC = red blood cells, HGB = hemoglobin, HCT = hematocrit, MCV = mean corpuscular volume, MCH = mean corpuscular hemoglobin, MCHC = mean corpuscular hemoglobin concentration, PLT = platelet, LYM = lymphocyte, NEUT = neutrophils, EOSI = eosinophils, BASO = basophils).

Table 2: Effect of sub-acute oral administration of *Terminalia chebula* on hepatic indices in wistar rats

Hepatic indices	Treatment (mg/kg)			
	DW(1ml/kg)	200	400	800
ALB (g/L)	39.60 \pm 1.72	43.20 \pm 0.97	35.20 \pm 1.59	41.75 \pm 2.18
ALP (IU/L)	113.20 \pm 6.73	152.00 \pm 8.99	370.00 \pm 43.37*	125.50 \pm 6.93
ALT (IU/L)	59.80 \pm 3.01	67.80 \pm 10.28	91.40 \pm 10.99	87.75 \pm 27.67
AST (IU/L)	292.80 \pm 79.90	297.20 \pm 57.60	171.20 \pm 30.88	213.00 \pm 10.75
BILD (μ mol/L)	0.22 \pm 0.07	0.16 \pm 0.07*	0.60 \pm 0.14*	0.60 \pm 0.13
BILT (μ mol/L)	2.14 \pm 0.50	2.56 \pm 0.25	3.46 \pm 0.80*	2.73 \pm 0.56
TP (g/L)	79.60 \pm 3.08	6.07 \pm 2.71	11.33 \pm 5.07	80.25 \pm 2.02

Data presented as Mean \pm SEM: n = 6, One Way ANOVA, followed by Dunnett's post hoc for multiple comparison *significantly different from the distilled water (DW) control at p < 0.05. DW = distilled water (ALB = albumin, ALP = alanine phosphatase, ALT = alanine transaminase, BILD = unconjugated bilirubin, BILT = conjugated bilirubin, TP = total protein).

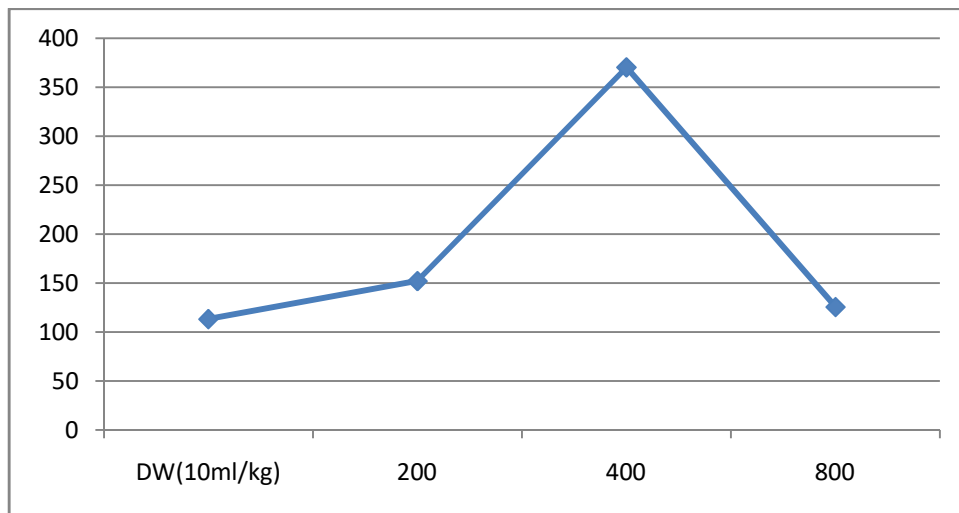


Figure 1: effect of ethanol leaf extract of *Terminalia chebula* on ALP of rat

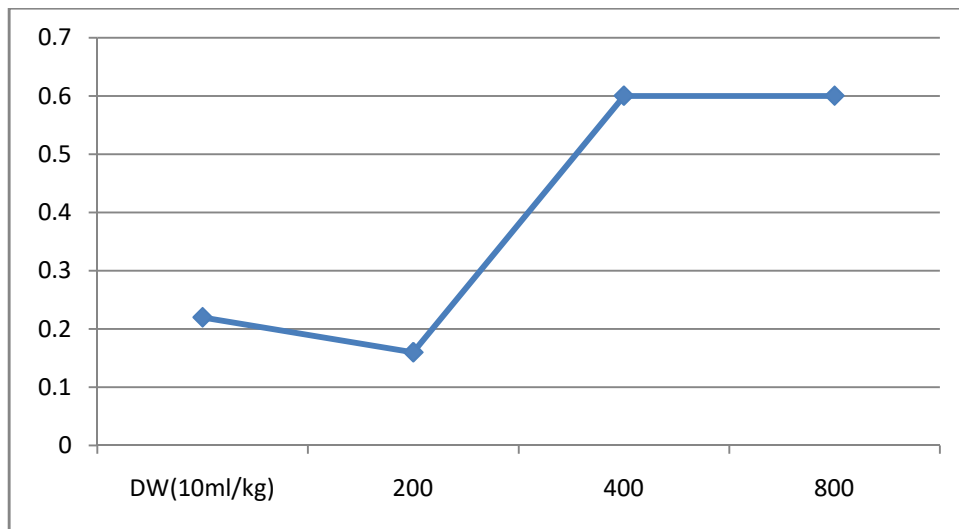


Figure 2: effect of ethanol leaf extract of *Terminalia chebula* on unconjugated (BILD) of rat

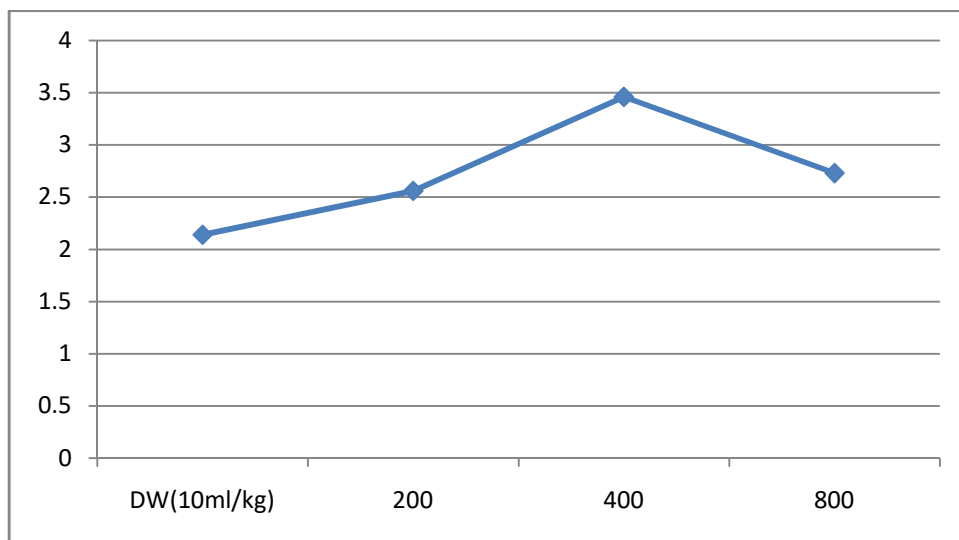


Figure 3: effect of ethanol leaf extract of *Terminalia chebula* on conjugated (BILT) of rat

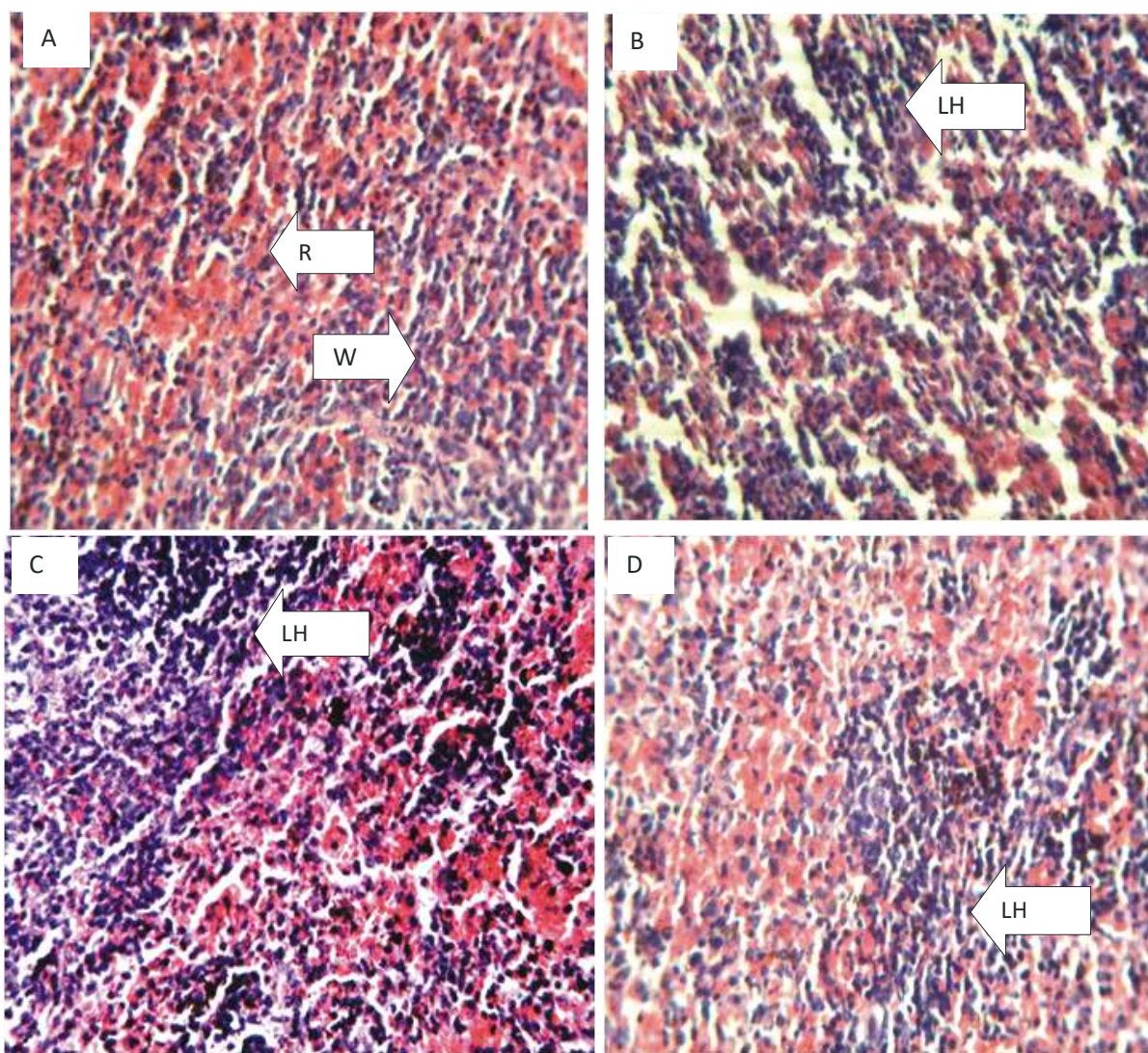


Figure 1: Micrograph of liver of Wistar rat H and E stain ($\times 100$). (a) Liver section of control group showing normal histology of the liver. (b) Liver section of group administered TC 200 mg/kg vascular congestion, and lymphocyte hyperplasia. (c) Liver section of group treated with TC (400 mg/kg) showing normal histology (d) Liver section of treated with 800 mg/kg Showing distortion of the histoarchitecture of the liver.

IV. DISCUSSION

There have been reports of accidental medicinal plant poisoning and over dose. In most cases this traditionally formulated drugs are consumed without appropriately establishing the dose that is safe for use. This has resulted into many untoward after effect^{10,25}. Hematological parameters are useful indices that can be employed to assess the toxic potentials of plant extracts in living systems^{11,12,13}. They can also be used to explain blood relating functions of chemical compound/plant extract¹⁵. Present result showed that ethanol leaf extract of *Terminalia chebula* caused a reduction in the level of red blood cells, hemoglobin, hematocrit, mean corpuscular volume, mean corpuscular hemoglobin and mean corpuscular hemoglobin concentration which means that it can significantly reduce oxygen carrying capacity of the blood and thus cause anemia. Anemia is a condition where the blood has insufficient red blood cells to carry oxygen from the lungs

to the rest of the body or not enough hemoglobin^{16,17,18}, the iron-rich protein that carries oxygen inside the red blood cells and gives blood its red color^{19,20,21,22}. Anemia takes several forms and may vary in severity and duration^{22,23}. Also reductions in packed cell volume (PCV) and red blood cell (RBC) were also observed in rats administered with the extract. This implies that *Terminalia chebula* could cause disturbances in osmoregulatory system of the blood cells and/or oxidative injury to the cell membrane. The extract could suppress the haemopoietic system. The reduction may have also occurred due to lysis of blood cells. Sule et al, 2012²⁴ also observed decrease in RBC, PCV, hemoglobin and lymphocytes in rats fed with extracts of *Acalypha wilkesiana*. The major functions of the white blood cell and its differentials are to fight infections, defend the body by phagocytosis against invasion by foreign organisms and to produce or at least transport and distribute antibodies

in immune response^{25,26}. The extract had no effect on white blood cell parameters, suggesting that it has no effect on the immune cells and the immune system. Hepatocyte membrane disruption is associated with membrane leakage of the hepatocyte cytosolic content which is manifested by a significant elevation of the serum marker enzymes of acute hepatocellular damage, i.e., ALT and AST, and ALP²⁷. However, ALT is the most reliable among these marker enzymes. AST is known to be present in abundance in the cardiac muscle, skeletal muscle, kidneys and testes, and ALP is abundant in the growing bone^{17,24,26,28}. Thus, any disease state affecting any of these extrahepatic tissues significantly elevates the serum levels of these enzymes. The plant did not cause an increase in the level ALT and AST meaning it may not membrane damage to the liver cells. There was significant increase in the serum level of ALP, unconjugated bilirubin (BILD), and conjugated bilirubin (BILT). Alkaline phosphatase (ALP) estimation is the most frequently used test to detect obstruction in the biliary system. Bilirubin is the main bile pigment in humans which, when elevated causes the yellow discoloration of the skin called jaundice²². Bilirubin is formed primarily from the breakdown of a substance called heme found in red blood cells. It is taken up from the blood, processed, and then secreted into the bile by the liver. Bilirubin (unconjugated or indirect) is bound to serum albumin and transferred to the liver where it is conjugated to glucuronate by glucuronyl transferase. Conjugated (direct) bilirubin is excreted into bile^{26,29}. There is normally a small amount of bilirubin in the blood in healthy individuals (<17µmol/L). Conditions which cause increased formation of bilirubin, such as destruction of red blood cells, or decrease its removal from the blood stream as in liver dysfunction, may result in an increase in the level of bilirubin in the blood^{22,25,29}. Increase in the level of ALP, BILD and BILT indicate that there was obstruction in the biliary system resulting, resulting in decrease in the clearance of bilirubin in the blood and elevation of conjugated and unconjugated bilirubin. Histology study showed slight vascular congestion and lymphocyte hyperplasia which agrees with other parameters that ethanol extract of the plant may have implication in the liver, particularly when taken for a sustained period of time.

V. CONCLUSION

Result from the study suggests that ethanol leaf extract of *Terminalia chebula* may be systemically toxic with tendency to biliary disease, especially jaundice.

ACKNOWLEDGEMENT

The authors wish to appreciate everyone who has contributed to the success of this study

REFERENCES

- [1]. Patil U.H., Gaikwad D.K. Phytochemical profile and antibacterial activity of stem bark of *Anogeissus latifolia*. Pharm. J. 2010;2:70-73.
- [2]. Dias F.D., Takahashi C.S. Cytogenetic evaluation of aqueous extracts of the medicinal plants *Alpinia mutans* rose (Zingiberaceae) and *Pogostemon hyneanus* benth (labitae) on

- wistar rats and *Allium cepa* (Liliaceae) root tip cells. Braz. J. Genet. 1994;17:175-180.
- [3]. Nath P., Yadav K.A. Acute and sub-acute oral toxicity assessment of the methanolic extract from leaves of *Hibiscus rosa-sinensis* L. in mice. J. Intercult. Ethnopharmacol. 2015;4:70-73.
- [4]. Eisenberg DM, David RB, Ettner SL. Trends in alternative medicine use in the United States, 1990-1997: results of a follow-up national survey. JAMA 1998;280:1569-1575.
- [5]. Obesity: preventing and managing the global epidemic. Report of a WHO consultation. World Health Organ Tech Rep Ser. 2000;894:1-253.
- [6]. Khosravi-Boroujeni H, Sarrafzadegan N, Mohammadifard N, Sajjadi F, Maghroun M, Asgari S, et al. White rice consumption and CVD risk factors among Iranian population. J Health Popul Nutr. 2013;31(2):252-261.
- [7]. Sadeghi M, Khosravi-Boroujeni H, Sarrafzadegan N, Asgari S, Rookhafa H, Gharipour M, et al. Cheese consumption in relation to cardiovascular risk factors among Iranian adults- IHHP Study. Nutr Res Pract. 2014;8(3):336-41.
- [8]. Tajfard M, Ghayour Mobarhan M, Rahimi HR, Mouhebat M, Esmaily H, et al. Anxiety, depression, coronary artery disease and diabetes mellitus; an association study in ghaem hospital, Iran. Iran Red Crescent Med J. 2014;16(9):e14589.
- [9]. Asgari S, Rafieian-Kopaei M, Shamsi F, Najafi S, Sahebkar A. Biochemical and histopathological study of the anti-hyperglycemic and anti-hyperlipidemic effects of cornelian cherry (*Cornus mas* L.) in alloxan-induced diabetic rats. J Complement Integr Med. 2014;11(2):63-9.
- [10]. Baradaran A, Nasri H, Rafieian-Kopaei M. Oxidative stress and hypertension: Possibility of hypertension therapy with antioxidants. J Res Med Sci. 2014;19(4):358-67.
- [11]. Vasan RS, Beiser A, Seshadri S, Larson MG, Kannel WB, et al. Residual lifetime risk for developing hypertension in middle-aged women and men: the Framingham Heart Study. JAMA 2002;287:1003-1010.
- [12]. Tewari, D; Mocan, A; Parvanov, E. D; Sah, A. N; Nabavi, S. M; Huminiecki, L; Ma, Z. F; Lee, Y. Y; Horbańczuk, J. O; Atanasov, A. G (2017). "Ethnopharmacological Approaches for Therapy of Jaundice: Part II. Highly Used Plant Species from Acanthaceae, Euphorbiaceae, Asteraceae, Combretaceae, and Fabaceae Families". *Frontiers in Pharmacology*. 8: 519.
- [13]. Saleem, A.; Husheem, M.; Härkönen, P.; Pihlaja, K. (2002). "Inhibition of cancer cell growth by crude extract and the phenolics of *Terminalia chebula* retz. Fruit". *Journal of Ethnopharmacology*. 81 (3): 327-336.
- [14]. Asgari S, Sahebkar A, Afshani M, Keshvari M, Haghjooyjavanmard Sh, Rafieian-Kopaei M. Clinical evaluation of blood pressure lowering, endothelial function improving, hypolipidemic and anti-inflammatory effects of pomegranate juice in hypertensive subjects. *Phytother Res*. 2014;28(2):193-199.
- [15]. Dossing M, Sonne J. Drug induced hepatic disorders: Incidence, management and avoidance. *Drug Safety*. 1993;9:441-9.
- [16]. World health organization. WHO media centre. Traditional medicine. WHO Fact sheet N°134. [cited in 2008 Dec].
- [17]. Gupta SS. (1994). Prospects and perspectives of natural plant products in medicine. *Indian J Pharmacol*.;2:1-12.
- [18]. Okokon JE, Nwafor PA. Antiulcer and Anticonvulsant Activities of *Croton zambesicus*. *Pakistan Journal of Pharmacological Sciences*; 2015. 4, 384-390.
- [19]. Recknagel RO, Glende EA. Jr. Carbon tetrachloride Hepatotoxicity: An Example of Lethal Cleavage. *Critical Reviews in Toxicology*; 1973. 2, 263-297.
- [20]. Doi, K., Kurabe, S., Shimazu, N. and Inagaki, M. (1991). Systemic Histopathology of Rats with CCl4-Induced Hepatic Cirrhosis, *Laboratory Animals*, 25,21-25.
- [21]. Dorman, H. J., Kosar, M., Karlos, K., Holm. Y. and Hittner, R. (2003). Antioxidant Properties and Composition of Aqueous Extracts From Menthaspecies, Hybrids, Varieties and Cultivars. *Journal of Agriculture Food and Chemistry*, 51, 4563-4569.

- [22]. Duraipandiyan, V. M., Ayyanar, L. and Ignacimuthu, S. (2006). Antimicrobial Activity of Some Ethnomedicinal Plants. *Asian Journal of Microbiologr*, 5, 334-337.
- [23]. Edson, R. S. and Terrell, C. L. (1999). The Aminoglycosides. *Mayo Clinic Proceedings*, 74, 519-28.
- [24]. Oyepata Simeon Joseph, Jude e Okokon, Opeyemi tosin Joseph (2018). Hepatoprotective activity of extract of Homalium Letestui stem against carbon tetrachloride-induced liver injury. *Advanced Herbal Medicine*. 3(4): 1-11.
- [25]. Eliwa, H. A., El-Denshary, E. S., Nada, S. A., Elyamany, M. F., Omara, E. A. and Asaaf, N. (2014). Evaluation of the Therapeutic Effect of Whey proteins on the Hepatotoxicity Induced by Paracetamol and Alcohol Co-administration in Rats. *International Journal of Progressive Pharmaceutical Research*,3, 295-314.
- [26]. Elliott, J., Barber, P.J., Rawlings, J.M. and Markwell, P.J. (1998). Effect of Phosphate and Protein Restriction on Progression of Chronic Renal Failure in Cats. *Journal of Veterinary Internal Medicine*,12, 221 – 228.
- [27]. Hassanean, H.A. and E.K. Desoky, 1992. An acylated isorhamnetin Glucoside from *Zygophyllum simplex*. *Phytochemistry*, 31: 3293-3294.
- [28]. Hruskova, J., L. Danes and V. Kliment, 1961. Venezuelan equine encephalomyelitis virus: Determination of inhalation LD₅₀ for guinea pigs and mice. *Acta Virologica*, 13: 203-208.