

Familial polycystic kidney disease in Nigeria: A report of two cases

*B. N. Okeahialam, S. D. Pam, J. E. Ekedigwe¹ and C. C. Ekwempu²

Departments of * Medicine, ¹Radiology and ²Obstetrics and Gynaecology
Jos University Teaching Hospital, Jos, Plateau State, Nigeria.

E-mail: basokeam@yahoo.com

Summary

A case of familial polycystic kidney disease is reported. Although isolated cases of adult polycystic kidney disease have been reported in our environment, no case to our knowledge has been reported with a familial link.

Polycystic kidney disease is said to be rare in Africans. Although it commonly terminates in chronic renal failure, it hardly features in the aetiopathogenesis of end stage renal disease requiring some form of renal replacement therapy in African series. This, some workers believe may be due to misdiagnosis and under reporting.

This report is to show that it may not be as rare as suspected, and that the familial link shown in the advanced countries is also applicable here. Case 1 was diagnosed in the course of evaluation of her clinical disease. Case 2, an aunt of Case 1, was diagnosed following investigation of a casual complaint of a painless abdominal mass in the wake of her senior brother's death from haemorrhagic stroke.

Key -words: *Familial, Polycystic kidney diseases, Nigeria.*

Résumé

Il s'agit d'un cas de la maladie polykystique des reins bien connu. Quoique des cas isolés des adultes atteints de la maladie polykystique des reins ont été rapportés dans notre milieu, aucun cas, autant que nous sachons, n'a été rapporté avec un lien familial. On dirait que la maladie polyskystique est rare chez des Africains. Quoiqu'elle, le plus souvent, provoque l'insuffisance renale chronique, c'est à peine si elle figure parmi l'aétiopathogène de la maladie des reins étape finale qui demande une forme de la thérapie de remplacement rénal dans les séries africaines. D'après quelques chercheurs, ceci pourrait être provoqué par erreur diagnostic⁷ et manque des informations.

L'objet de ce rapport est de montrer qu'elle n'est pas aussi rare comme on doit y attendre, et que ce lien familial montré dans les pays industrialisés est également applicable. Le 1^{er} cas était diagnostiqué au cours d'évaluation de sa maladie clinique. Le deuxième cas, une tante du premier cas, était diagnostiqué à la suite d'une enquête effectuée sur une plainte insouciant de d'abdominal de masse sans douleur à la suite de la mort de son frère aîné provoquée par une attaque hémorragique.

Introduction

Polycystic kidney disease (PKD) has been recorded since the 19th century, during which time its genetic basis was established¹. It has however been said to occur rarely

in Africa among the blacks². In 1989, Akinsola et al reported only one case of polycystic disease out of 100 cases with chronic renal failure³. Down the line in 1992, in an autopsy study of chronic renal failure cases, Ojo et al did not record a case of PKD⁴. These studies tend to corroborate the assertion of the rarity of PKD among black Africans, since it is said to be the most frequent genetic cause for adult renal failure⁵. Being a genetically linked disease, it can be inherited; either in autosomal dominant or recessive fashion⁶. Not all cases of PKD are familial, as cases have been known to arise sporadically. Some are also acquired in adult life as a consequence of ageing, dialysis, drugs and hormones⁷. The interest in reporting these cases is the familial expression. Both cases are of the same gender (female) and related; one the aunt of the other.

Case reports:

1. B.O. was a single adult female; an auxiliary nurse who presented in December 2002 at 37 years. She belonged to the Ibo ethnic group of Nigeria. Her problems at the time were a year history of body itching, dizziness and impaired vision of 2 months duration. There was also facial puffiness; worse on rising. There was no obvious cause of the itching. She had been diagnosed hypertensive at 36 years but did not apply herself consistently to prescribed treatment. She also had pruritus vulvae with recurrent whitish mucoid vaginal discharge. She denied any family history of similar illness.

On examination, she was overweight, puffy, mildly pale and with peripheral oedema. Central nervous system examination showed no abnormality. The only abnormal finding in the cardiovascular system was an elevated blood pressure of 200/114 mm Hg. supine and 196/110 mm Hg. sitting. Abdominal examination revealed a uterine mass (24 week size).

Blood investigations (full blood count, electrolytes, blood urea nitrogen and fasting blood sugar) were normal. However she had hypercholesterolaemia. Electrocardiogram (ECG) showed left atrial enlargement only. Chest X-ray was normal. Abdominal ultrasound was reported as showing cystic masses in the uterus, bilateral polycystic kidneys (Figure 1), and a right adnexal mass that was suspected to be ovarian.

She was given Lisinopril 10 mg. daily, Hydrochlorothiazide 25 mg. daily, Nifedipine retard 20 mg. daily and Simvastatin 20 mg. nocte. For her genital infection, she was given Doxycycline and Metronidazole. In

*Correspondence

addition, a gynaecological consultation was arranged. She had surgery (myomectomy) and 16 of the cystic masses were shelled out. She abandoned medical care for native/spiritual treatment on the advise of friends and relations who convinced her that her illness was a spiritual affliction. Early in 2005, she suffered a transient ischaemic attack. She was subsequently lost to follow up.

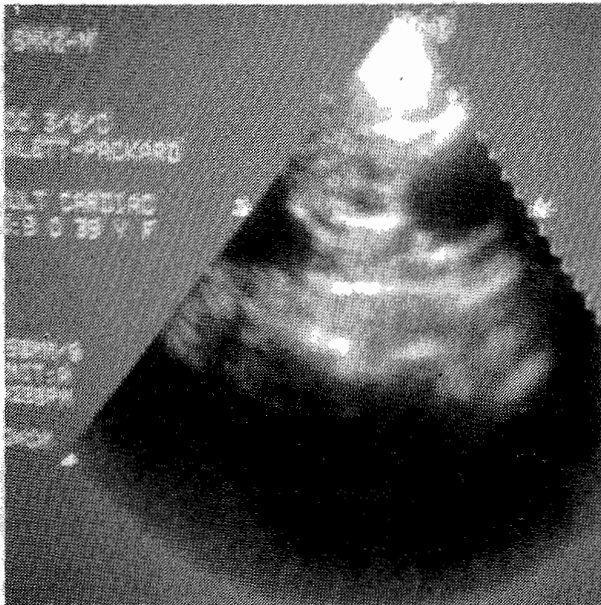


Figure 1 is from Case 1, B O. It is an ultrasound image of the kidney showing echoluscent shadows with rear wall enhancement in both poles; suggestive of true cysts.

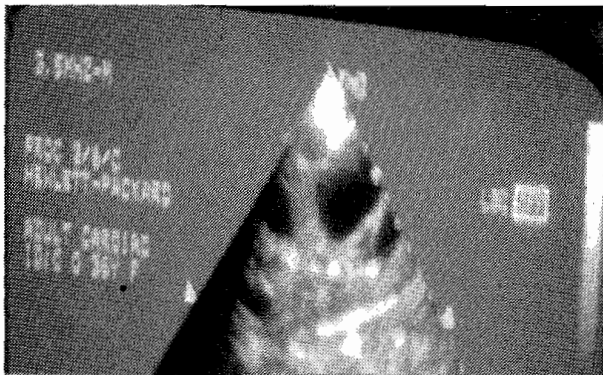


Figure 2 is from Case 2, C O. It shows sa eco ul

2. C. O. an aunt of B. O. (youngest sister of B. O.'s father) presented in 2004 at 48 years; soon after one of her senior brothers died of a haemorrhagic stroke, in the background of long standing hypertension. She complained of a mass in the epigastrium which protruded intermittently. There was no other symptom. On examination, all systems were normal except the abdomen where a 12 cm. hepatomegaly was discovered. All tests (electrolytes, blood urea nitrogen, liver function test, full blood count and prothrombin time) were normal. Stool microscopy returned normal. However on abdominal ultrasound, multiple cysts were seen

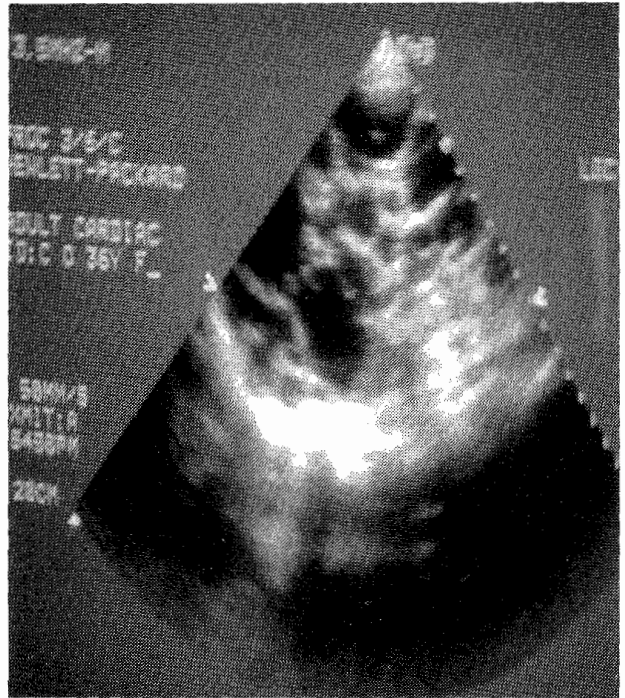


Figure 3 is from case 2, CO. It shows multiple cystic areas of varying sizes in the liver, in keeping with cystic liver.

in the kidneys (Figure 2), liver (Figure 3) and spleen. Other abdominal organs were normal. She has remained normal and is being followed up quarterly.

Comments

Autosomal dominant PKD is said to be the most common inherited renal disorder⁸. The exact epidemiology of this illness is not known in black Africans. However it affects 4 – 6 million people world wide (1 in 800 live births), and is the reason for dialysis in 7 – 10% of cases⁷. In Nigeria, a few cases have been reported from Ibadan⁹ and Enugu¹⁰. The interesting thing about the latter is that the cases were reported among patients of the Ibo ethnic group; the same tribe to which our cases belong.

Although the name would suggest a localized renal disease, it is known to be multi-systemic. The brain, liver, pancreas, heart have been reportedly affected⁸. The autosomal recessive variety is hardly compatible with life, as foetal and neonatal death is common place⁸. The autosomal dominant variety has two types I and II. The type II presents late, and progresses slowly to renal failure⁸. Case 1 presented typically with hypertension and urogenital infection apart from cysts in the kidney and uterus. Uterine involvement is not commonly reported in literature. She later suffered a cerebrovascular disease, to which is predisposed given her hypertension and hypercholesterolaemia. The fact that in her late 30s, her renal function remained normal, despite other complications suggests mild disease (Type II). The only symptom in Case 2 was an abdominal mass. Given her age at presentation, and apparent good health, she could also be of the type II variety⁸.

The diagnosis was made following the finding of multiple cysts in organs such as the liver, spleen and uterus. In addition, seeing at least 2 cysts in each kidney of suspected cases is said to constitute ultrasound diagnostic criteria⁸. Both patients satisfy this criterion (see Figs 1 and 2).

In conclusion, PKD which is still sporadically reported in Africa could also run in families as elsewhere.

Acknowledgement: Dr E. I Agaba is appreciated for providing reprints to references 1, 6 and 7.

References

1. Torres VE, Watson ML. Polycystic kidney disease: antiquity to the 20th century. *Nephrol. Dial. Transplant.* 1998; 13: 2690 – 2696.
2. Thomson PD. Renal problems in black South African children. *Paediatr. Nephrol.* 1997; 11: 508 – 512.
3. Akinsola W, Odesanmi WO, Ogunniyi JO, Ladipo GO. Diseases causing chronic renal failure in Nigerians – a prospective study of 100 cases. *Afr. J. Med. Med. Sci.* 1989; 18: 131 – 137.
4. Ojo OS, Akinsola AA, Nwosu SO, Odesanmi WO. The pathological basis of chronic renal failure in Nigerians. An autopsy study. *Trop. Geog. Med.* 1992; 44: 42 – 46.
5. Torra R. Polycystic kidney disease. *e. medicine* 2004 (Nov. 18).
6. Neuman HPH. The spectrum of renal cysts in adulthood – discussion of eight cases. *Nephrol. Dial. Transplant.* 1999; 14: 2234 – 2244.
7. Wilson PD. Polycystic kidney disease (Mechanisms of Disease). *N. Engl. J. Med.* 2004; 350: 150 – 164.
8. Demetrios K, Tziakouri C, Anninou K, Eleftherios A, Koptides M, Nicotau A, Deltas CC, Pierides A. Autosomal dominant polycystic kidney disease – type 2. Ultrasound, genetic and clinical correlations. *Nephrol Dial. Transplant.* 2000; 15: 205 – 211.
9. Roberts OA, Shittu OB, Kadiri S. Polycystic kidney disease in pregnancy in a Nigerian woman. *Trop. J. Obst. Gynaec.* 2001; 18: 40 – 42.
10. Onuigbo WI. Comparative study of adult polycystic kidney disease. *Ethiop. Med. J.* 2001; 39: 247-249.