

Histological study on the protective effect of *Moringa oleifera* leaf extract on indomethacin-induced degenerated testes and uterus in albino rat

Ephron E Yerebmede¹, James O. Adisa¹, Solomon M. Gamde^{1,2*}, David O. Ishola³, Gloria H. Dachollom¹, Khadija M. Mohammed¹

¹Department of Medical Laboratory Science, University of Jos, Plateau State, Nigeria

²Department of Medical Laboratory Science, Bingham University Karu, Nasarawa State, Nigeria

³Department of Vetnary Medicine, Usman Danfodiyo University Sokoto, Nigeria

*Corresponding Author:

Solomon M. Gamde, Department of Medical Laboratory Science, University of Jos, Plateau State, Nigeria

E-MAIL: solomonmatthias85@gmail.com



COPYRIGHT: ©2023 EE Yerebmeded et al. This is an open-access journal, and articles are distributed under the terms of the Creative Commons Attribution License CC-BY 4.0. (<https://creativecommons.org/licenses/by/4.0/>) which permits unrestricted use, distribution, and reproduction in any medium, provided the original authors and source are credited.

Date of Submission: 10/05/2023

Date of Review: 23/09/2023

Date of Acceptance: 08/12/2023

ABSTRACT

Background: Indomethacin has analgesic and antipyretic properties. It is a common treatment for pain and rheumatoid diseases, but it has many side effects. We speculate that the natural antioxidants of *Moringa oleifera* could be a remedy for the long list of side effects. This study aimed to determine the possible protective effect of *Moringa oleifera* leaf extract on the indomethacin-induced degenerated testes and uterus in albino rat.

Methods: Forty-eight white albino rats were assigned randomly into six groups consisting of eight rats. Group I was the Normal control. Group II was animals induced with indomethacin but not treated. Group III was dosed with 500 mg/kg *Moringa oleifera* leaf extract while Groups IV-VI were induced with indomethacin and treated with 100, 250, and 500 mg/kg *Moringa oleifera* leaf extract respectively for 28 days. Animals were euthanized after the treatment period. The uterus and testes were excised and processed using the paraffin wax method and stained with haematoxylin and eosin.

Results: Animals exposed to indomethacin became drowsy and lethargic with deep red teary eyes. The first mortality was recorded among animals administered with indomethacin without treatment. Histopathology of the testes showed that indomethacin caused degeneration of the seminiferous tubules and diminished the spermatozoa. The histology of the uterus was distorted, the endometrium and myometrium layers of the uterus were disintegrated. However, animals treated with *Moringa oleifera* showed dose-related improvements in the histology of the testes and uterus compared to the control group.

Conclusion: *Moringa oleifera* leaf extract improved the histology of indomethacin-induced toxicity of the testes and

uterine in white albino rats.

KEYWORDS: *Moringa oleifera*, Indomethacin, Histopathology, NSAID

INTRODUCTION

Indomethacin is one of the most used non-steroidal anti-inflammatory drugs (NSAIDs) with marked analgesic, anti-inflammatory, and antipyretic properties prescribed worldwide. [1] In the United States, about 5–10% of people use NSAIDs frequently. [2] Non-steroidal anti-inflammatory drugs are used for their analgesic and antipyretic effects to relieve pains and treat rheumatoid diseases [3], which bring about the inhibition of prostaglandins that is abundant in the male reproductive tract. [4]

Prostaglandins regulate sperm metabolism and increase the contractility of the epididymal tubule. [5] One of the main mechanisms by which NSAIDs work to reduce inflammation is by inhibition of the cyclooxygenase pathway 2 (COX 2) enzyme which is responsible for the conversion of arachidonic acid to prostaglandin. [6, 7]

Moringa oleifera Lam (Moringaceae) is a rich source of proteins, flavonoids, and polyphenols. [8] The leaves are the most used parts in traditional medicine for diabetes, hypertension, and infertility. [9] In Nigeria, it is a common practice to find the extract being sold in the market as a raw drug due to its acclaimed medicinal uses. [10] Decoctions of *Moringa oleifera* are used in folklore medicine as gastrointestinal tract protection against NSAIDs. [11] Unfortunately, no single study is reported on the protective effect of *Moringa oleifera* on the toxicities of the testes and uterus that was indomethacin-induced. This study aimed to determine the possible protective effect of *Moringa oleifera* leaf extract on the indomethacin-induced degenerated testes and uterus in

albino rat.

MATERIALS AND METHOD

Plant Preparation

The fresh plant was found in the University of Jos Herbarium, Department of Plant Science with voucher number UJH-17000281. *Moringa oleifera* was extracted using the Maceration method with little modification by Thomas Yakubu, Department of Pharmacognosy, University of Jos. Three hundred grams of the plant powder were weighed and soaked in distilled water. The mixture was allowed to stand overnight and filtered using non-absorbent cotton wool on a Buchner flask. The filtrate was evaporated to dryness using a water bath and a hot air oven at a controlled temperature of 60°C.

Animals groups:

Albino rats (*Rattus albus*) were acquired from the Animal House, Department of Pharmacology, University of Jos, Nigeria. The rats were housed under standard laboratory conditions in a controlled room with 12 hours of light; 12 hours of the dark cycle at room temperature of 25°C. Animals were fed with chow and water ad libitum.

EXPERIMENTAL DESIGN

A total of forty-eight animals were assigned into six groups consisting of 8 rats each in the experimental and control groups. The weights of animals were taken with the aid of a weighing scale. Changes in the quantity of food and water consumption were measured by measuring the food and water given to each group of animals before and after the treatment.

The grouping is as follows:

Group I was the negative control, fed with Grower mash and water only

Group II was treated with Indomethacin after 48 hours fasting period

Group III was treated with 500 mg of *Moringa oleifera* extract.

Group IV was treated with 100 mg/kg *Moringa oleifera* after Indomethacin exposure

Group V was treated with 250 mg/kg *Moringa oleifera* after Indomethacin exposure

Group VI was treated with 500 mg/kg *Moringa oleifera* after Indomethacin exposure

The treatment lasted for 28 days.

Histopathological Study

The selected organs, the uterus, and testis were excised after the animals were anesthetized and they were fixed in 10% buffered formalin for 24 hr. The organs were dehydrated in three changes of ethanol. Three changes of

xylene and molten paraffin wax. Thin sections were cut and stained with hematoxylin and eosin (H&E) as described by Gamde et al. [12]

Statistical analysis

Statistical data were analysed using SPSS Windows version 20.0 software and one-way analysis of variance (ANOVA) was carried out for the comparison among experimental groups. P value ≤ 0.05 was statistically significant.

RESULT

After fasting for 48hrs, the animals became cannibalistic, feeding on some of the weaker animals in some groups. The aggressive behaviour escalated after the indomethacin administration. After 24 hrs of indomethacin administration, the animals were weak and sluggish, and seemingly suffering from emesis. The initial treatment with *Moringa oleifera* caused watery stool formation, but diarrhoea ceased as treatment continued.

Table 1 Indicates the general observations of the animals during and after the oral administration of indomethacin and the extract.

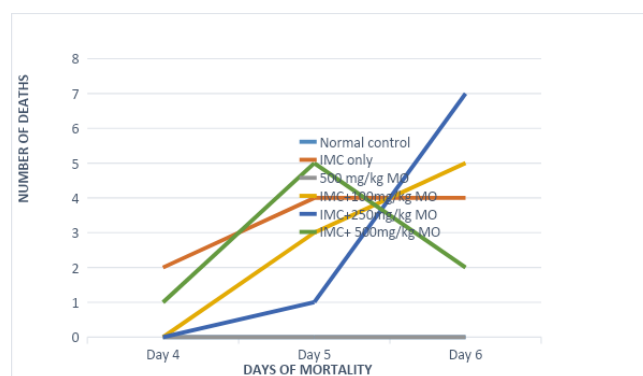


Figure 1: Mortality rate during the experiment.

Figure 1 shows that the first mortality was recorded in the animals administered with indomethacin only while the least was recorded in indomethacin-induced animals treated with 500 mg/kg *Moringa oleifera*.

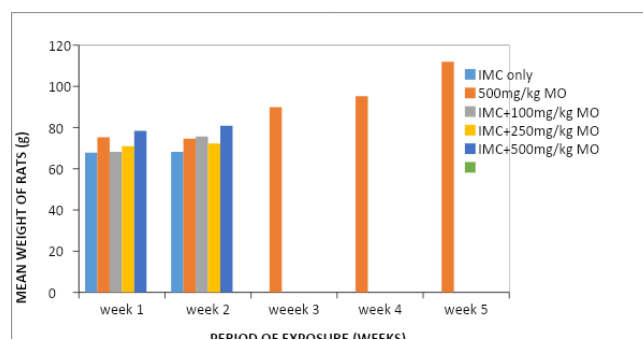


Figure 2: Weight changes among different groups.

TREATMENTS	PHYSICAL AND BEHAVIORAL OBSERVATIONS
Dis-tilled water	Smooth fur appearance, rats were active with normal bright red eye colour and formed stool
IMC:	
Before Administration	On fasting, animals became weak and sluggish with spiky fur and semi-formed stool
After Administration	The animals were sluggish with black watery stool and deep red teary eyes
500mg of MO only	
Before Administration	The animals were active, with smooth bright red eyes and normal, black-formed stool
After Administration	Animals were hyperactive immediately after administration with watery stool production that became formed on continuous treatment with MO
IMC + 100mg of MO	
Before Administration	The animals were weak from IMC treatment with spiky fur, deep teary red eyes, and watery stool.
After Administration	The animals continued weakness. with increased watery stool production immediately after MO administration
IMC +250mg Of MO	
Before Administration	The animals had smoother fur than MO with increased brightness in eye colour.
After Administration	The animals were more active and with semi-formed stool production
IMC +500mg of MO	
Before Administration	The animals had smoother fur than MO with increased brightness in eye colour.
After Administration	Didn't survive after the IMC administration

Figure 2 shows that the indomethacin-induced animals treated with 500 mg/kg of Moringa oleifera and the 500 mg/kg of Moringa oleifera had the highest relative weight gain in the first and second experimental weeks. However, the third and fourth weeks documented that the animals exposed to 500 mg/kg Moringa oleifera extract and the normal negative control had the highest relative weight gain.

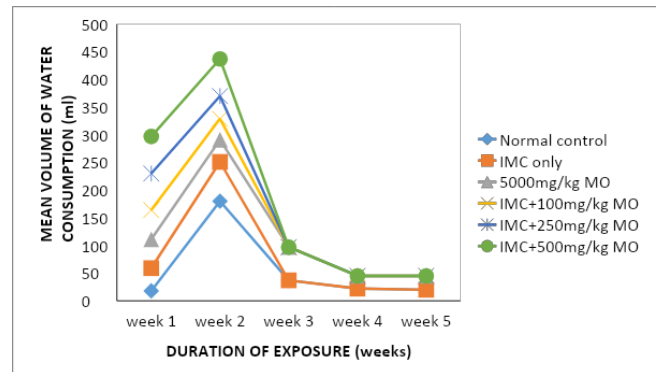


Figure 3: Mean Water Consumption (ml)

Figure 3 showed that the indomethacin-induced animals treated with 500 mg/kg Moringa oleifera had the highest water intake compared to the normal control.

The collapsed seminiferous tubules (black arrow) are separated by disintegrated connective tissue. However, there are some spermatids (blue arrow) in the extract-treated groups.

Figure 4 shows a normal histological section of the testis exhibiting seminiferous tubules separated by connective tissue embedded in the interstitial cells. The seminiferous tubules are seen to contain spermatogonia (red arrow). There are also spermatids (blue arrow) in the lumen of the tubules. Animal treated with IMC: Testis contains collapsed seminiferous tubules (black arrow) separated by disintegrated connective tissue. The histological organization of the seminiferous tubules is distorted by indomethacin and there are some spermatogonia, primary spermatocytes, and spermatids. Animals treated with 500 mg/kg MO showed several seminiferous tubules separated by connective tissue and individual tubules showed layers of spermatogonia, spermatocytes, and spermatids. Animals treated with 100 mg/kg MO: The seminiferous tubules showed a thin layer of spermatogonia and seemingly disintegrating spermatocytes and spermatids. Animals treated with 250 mg/kg MO show evident separation of the spermatogonia, spermatocytes, and spermatids. Animals treated with 500 mg/kg MO show loss of architecture in the seminiferous tubules. There is a mix of the various developmental stages of the sperm cells (H&E. X400).

Figure 5 shows normal histological section of the uterine lumen with its epithelium (blue arrow). Beneath this layer there are several uterine glands and a small portion of the myometrium adjacent to the endometrium. Animals treated

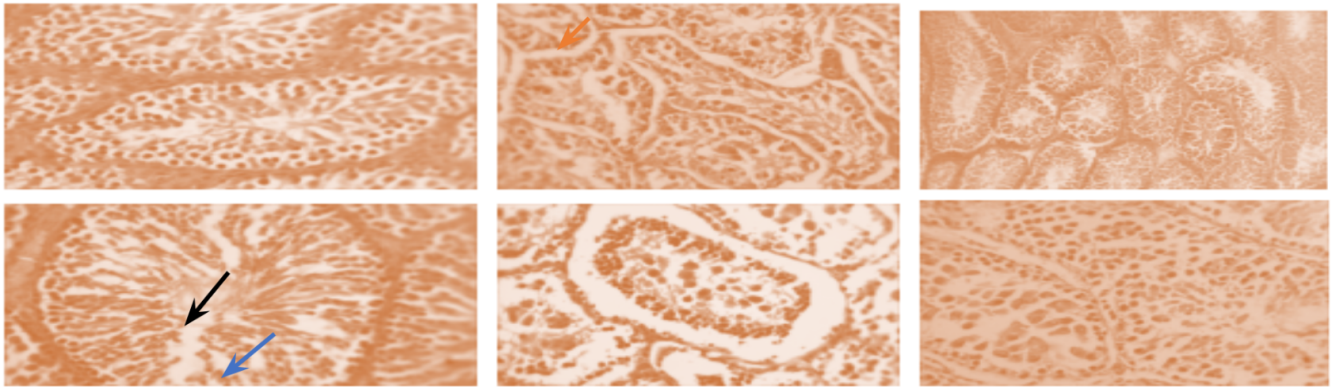


Figure 4: The indomethacin-induced testis with degenerated seminiferous tubules. The collapsed seminiferous tubules (black arrow) are separated by disintegrated connective tissue. However, there are some spermatids (blue arrow) in the extract-treated groups.




Figure 5: Massive Infiltration of polymorphonuclear leukocytes (green arrow), particularly in the IMC-induced endometrium (blue arrow), and the muscular layer (black arrow) in the myometrium showed a disintegrating separation. However, extract treated group showed evident regeneration of the endometrium and myometrium in a dose-related manner.

with IMC shows the endometrium surrounded by the myometrium (black arrow). There was a massive infiltration of polymorphonuclear leukocytes (green arrow), particularly in the endometrium. The muscle layers in the myometrium show a disintegrating separation. Animals treated with 5000 mg/kg MO shows the uterine lumen with its epithelium. Beneath this layer are several uterine glands and a small portion of the myometrium adjacent to the endometrium. Animals treated with 100 mg/kg MO shows evident degeneration of the endometrium and myometrium. Animals treated with 250 mg/kg MO shows evident degeneration of the endometrium and myometrium. Animals treated with 500 mg/kg MO shows evident degeneration of the endometrium and myometrium (H&E, 400 \times).

DISCUSSION

Our result showed indomethacin-induced partial to severe damage to the testes and uterine tissues in albino

rats. The indomethacin-induced animals presented a spiky fur appearance accompanied by semi-formed stool which progressed to diarrhea, and some died. The animals became lethargic and drowsy with red teary eyes. Animals exposed to *Moringa oleifera* extract indicated a purgative effect of the extract without any transcribed weakness. The watery stool was seized with continued oral administration of MO extracts. This effect may be due to the restraint in prostaglandin synthesis and the relaxation of intestinal motility.^[13]

Being an experimental study, in our analysis, there was no significant distortion in the gross anatomy of the testes across the extract-treated groups. However, the administration of MO extract increased the relative testicular weights as the experiment progressed. It is already established that indomethacin-induced oxidative stress which may be capable of disrupting the steroidogenic capacity of Leydig cells as well as the capacity of the germinal epithelium to differentiate normal spermatozoa. A wide variety of different

xenobiotics have also been shown to induce oxidative stress in the testes in concert with the suppression of antioxidant spermatids. [14] Previous studies have also reported a total loss of the seminiferous tubules from the connective tissues and marked destruction of spermatogonia, spermatocytes, and spermatids. [14, 15] However, oral administration of the extract worked similarly to conventional drugs. [16, 17] In agreement with previous studies, *Moringa oleifera* promotes a variety of antioxidant enzymes and testicular biomarkers that improve reproductive potential. [18, 19] The protective effect of *Moringa oleifera* on degenerative changes induced by indomethacin in the testicular germ cells might have been from inhibition of the lipid peroxidation and DNA damage caused by reactive oxygen radicals. [20–23]

In the present study, indomethacin-induced animals showed massive infiltration of polymorphonuclear leukocytes, particularly in the endometrium. The smooth muscles in the myometrium showed disintegrating separations. The endometrium villi projections were also reduced. Our findings agreed with the previous study that reported cells exposed to high concentrations of indomethacin were severely damaged, proved by marked cellular necrosis, nuclear pleomorphism, margination of chromatin, swollen mitochondria, and reductions in the number of microvilli, smooth endoplasmic reticulum proliferation, and cytoplasmic vacuolation. [24] These pathological changes may cause the death of the animals we recorded before the histological sampling. The extract did not produce any visible deleterious effect on the rat's uterus. Besides, the extract has shown abortifacient properties as reported by Shinku et al., D Nath et al., Sethi N et al. [25–27] The *Moringa oleifera* leaf extract we used in the present study could be responsible for the cytoprotective effect on the endometrium.

CONCLUSION

Our result showed that *Moringa oleifera* leaf extract ameliorates indomethacin-induced testicular and uterine toxicities. Hence, further studies are to ascertain the active agents.

REFERENCES

- Atiya A, Majrashi T, Akhtar S, Khan AA, Asiri AM, Al-Zahrana HJ et al. The value of Genus *Acacia* in arid and semi-arid environments for treating chronic inflammatory diseases. *Phytomedicine Plus*. 2022;2(3):100315.
- Davis JS, Lee HY, Kim J, Advani SM, Peng HL, Banfield E et al. Use of non-steroidal anti-inflammatory drugs in US adults: changes over time and by demographic. *Open Heart*. 2017;4:550.
- Paglia M, Silva MT, Lopes LC, Barberato-Filho S, Mazzei LG, Abe FC et al. Use of corticoids and non-steroidal anti-inflammatories in the treatment of rheumatoid arthritis: Systematic review and network meta-analysis. *PLoS One*. 2021;16(4):248866.
- Tran-Guzman A, Culty M. Eicosanoid Biosynthesis in Male Reproductive Development: Effects of Perinatal Exposure to NSAIDs and Analgesic Drugs. *Front Toxicol*. 2022;4:842565.
- Hoxha M, Barbonetti A, Zappacosta B. Arachidonic Acid Pathways and Male Fertility: A Systematic Review. *Int J Mol Sci*. 2023;24(9):8207.
- Qureshi O, Dua A, Inhibitors C. StatPearls [Internet. StatPearls Publishing; 2023. Available from: <https://www.ncbi.nlm.nih.gov/books/NBK549795/>.
- Wang B, Wu L, Chen J. Metabolism pathways of arachidonic acids: mechanisms and potential therapeutic targets. *Sig Transduct Target Ther*. 2021;6:94.
- Pareek A, Pant M, Gupta MM, Kashania P, Ratan Y, Jain V et al. *Moringa oleifera*: An Updated Comprehensive Review of Its Pharmacological Activities, Ethnomedicinal, Phytopharmaceutical Formulation, Clinical, Phytochemical, and Toxicological Aspects. *Int J Mol Sci*. 2023;24(3):2098.
- López M, Ríos-Silva M, Huerta M, Cárdenas Y, Bricio-Barrios JA, Díaz-Reval MI et al. Effects of *Moringa oleifera* leaf powder on metabolic syndrome induced in male Wistar rats: a preliminary study. *Journal of International Medical Research*. 2018;46(8):3327–3363.
- Udeogu C, Ejiofor CC, Nwakulite A. Effects of *Moringa oleifera* leaves methanolic extract on alloxan-induced diabetic Albino rats. *Asian Journal of Research in Medical and Pharmaceutical Sciences*. 2019;7(2):1–8.
- Dalhouni W, Guesmi F, Bouzidi A, Akermi S, Hfaiedh N, Saidi I. Therapeutic strategies of *Moringa oleifera* Lam. (Moringaceae) for stomach and forestomach ulceration induced by HCl/EtOH in rat model. *Saudi J Biol Sci*. 2022;29(6):103284.
- Gamde SM, Wali U, Garba A, Agom DD, Ayuba HM. Histopathological And Biochemical Effects of Aqueous Fruit Extract of *Balanite Aegyptiaca* on Selected Organs of Mice. *International Journal of Human and Health Sciences*. 2023;7(3):54–63.
- Torres-Castillo JA, Sinagawa-García SR, Martínez-Ávila GC, López-Flores AB, Sánchez-González EI, Aguirre-Arzola VE et al. *Moringa oleifera*: phytochemical detection, antioxidants, enzymes and antifungal properties. *International Journal of Experimental Botany*. 2013;82:193–202.
- Houda A, Nyaz S, Sobhy M, Bosilah H, Romeo A, Michael P. Male Reproductive Anatomy. In: *Seminiferous tubules and spermatogenesis*. London, UK.: Intech Open; 2021. .

15. Adamczewska D, Słowikowska-Hilczer J, Walczak-Jędrzejowska R. The Fate of Leydig Cells in Men with Spermatogenic Failure. *Life*. 2022;12(4):570.
16. Kou X, Li B, Olayanju JB, Drake JM, Chen N. Nutraceutical or Pharmacological Potential of *Moringa oleifera* Lam. *Nutrients*. 2018;10(3):343.
17. Paikra BK, Dhongade H, Gidwani B. Phytochemistry and Pharmacology of *Moringa oleifera* Lam. *J Pharmacopuncture*. 2017;20(3):194–200.
18. Mohlala K, Ofor U, Monageng E, Takalani NB, Opuwari CS. Overview of the Effects of *Moringa oleifera* Leaf Extract on Oxidative Stress and Male Infertility: A Review *Applied Sciences*. 2023;13(7):4387.
19. Obembe OO, Raji Y. Effects of aqueous extract of *Moringa oleifera* seed on cadmium-induced reproductive toxicity in male Wistar rats. *Afr Health Sci*. 2018;18(3):653–663.
20. Ceci R, Maldini M, Olson ME, Crognale D, Horner K, Dimauro I et al. *Moringa oleifera* Leaf Extract Protects C2C12 Myotubes against H₂O₂-Induced Oxidative Stress. *Antioxidants*. 2022;11(8):1435.
21. Saki M, Villiers D, Ntsapi H, Tiloke C, C. The Hepatoprotective Effects of *Moringa oleifera* against Antiretroviral-Induced Cytotoxicity in HepG2 Cells: A Review. *Plants*. 2023;12(18):3235.
22. Sadek KM. Chemotherapeutic efficacy of an ethanolic *Moringa oleifera* leaf extract against chromium-induced testicular toxicity in rats. *Andrologia*. 2014;46(9):1047–54.
23. Amina M, Bhat RS, Al-Dbass AM, Musayeib NM, Fahmy R, Alhadlaq L et al. The protective effect of *Moringa oleifera* plant extract against glutamate-induced DNA damage and reduced cell viability in a primary retinal ganglion cell line. *PeerJ*. 2021;9:11569.
24. Sorensen EM, Acosta D. Relative toxicities of several nonsteroidal anti-inflammatory compounds in primary cultures of rat hepatocytes. *Journal of Toxicology and Environmental Health, Part A Current Issues*. 1985;16(3-4):425–465.
25. Shinku F, Dafiell CN, Oo M, Ekwere EO. Ethanolic root extract of *Moringa oleifera* lam causes Histomorphological changes in the ovary and uterus of female Wistar rats. *International Journal of Recent Scientific Research*. 2016;7(3):9305–9309.
26. Nath D, Sethi N, Singh RK, Jain AK. Commonly used Indian abortifacient plants with special reference to their teratologic effects in rats. *Journal of Ethnopharmacology*. 1992;36(2):147–154.
27. Sethi N, Nath D, Shukla S, Dyal R. Abortifacient activity of a medicinal plant *Moringa oleifera*. *Ancient science of life*. 1988 01;7:172–4.

How to cite this article: Yeremede EE, Adisa JO, Gamde SM, Ishola DO, Dachollom GH, Mohammed KM. **Historical study on the protective effect of *Moringa oleifera* leaf extract on indomethacin-induced degenerated testes and uterus in albino rat.** *Perspectives in Medical Research*. 2023;11(3):29-34
DOI: [10.47799/pimr.1103.06](https://doi.org/10.47799/pimr.1103.06)

Sources of Support: None; , **Conflict of Interest:** Nil;