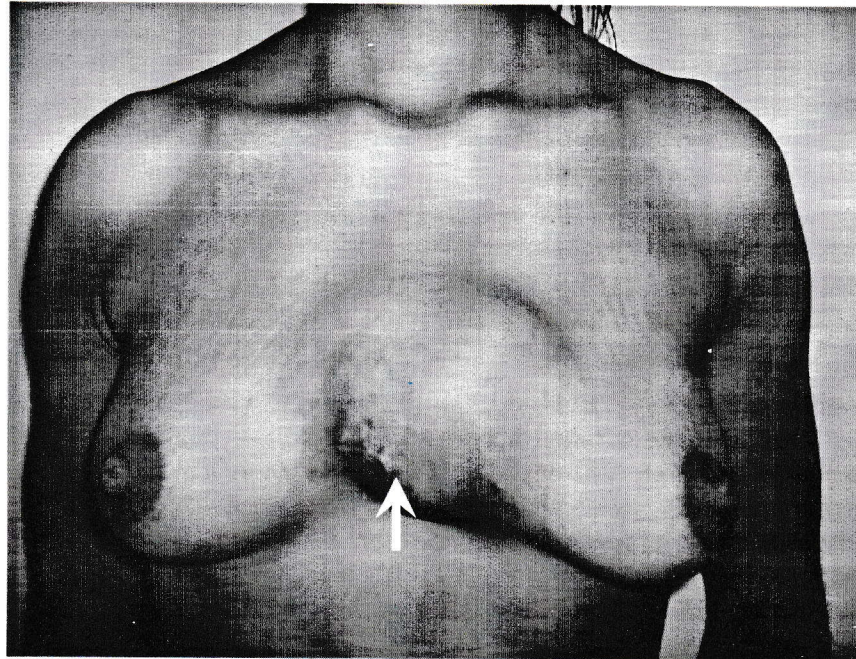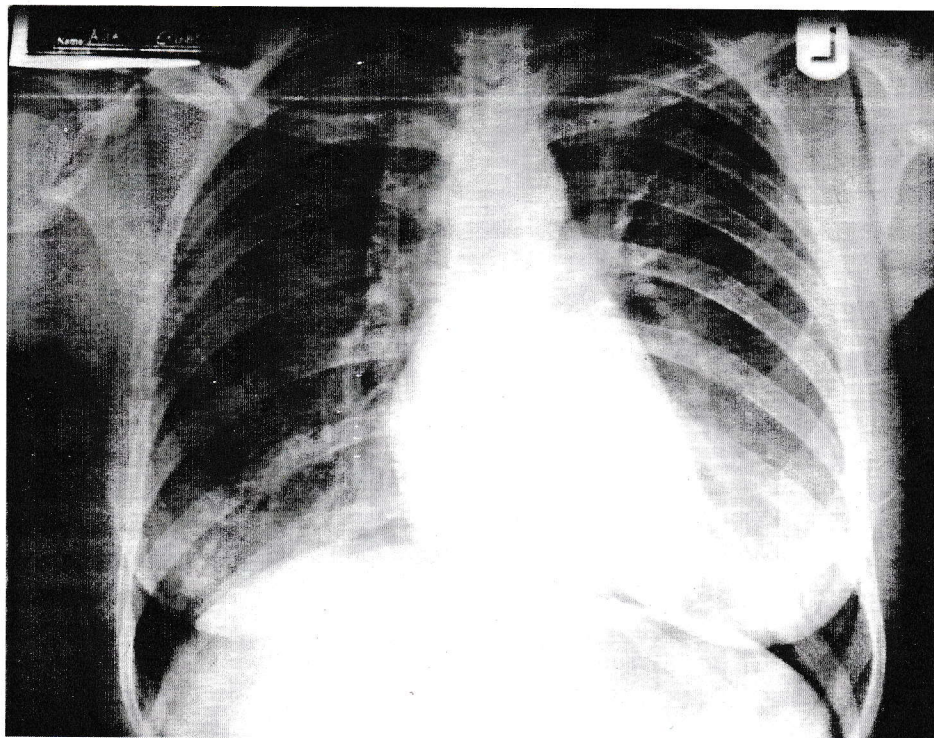


**Fig. 1:** Picture showing a hard mass overlying the middle of the sternum (white arrow)



**Fig. 2:** Frontal chest radiograph showing a soft tissue mass overlying the cardiac shadow. There is no obvious lung parenchyma disease. The heart size is normal with a cardiothoracic ratio of 11.5/25.5